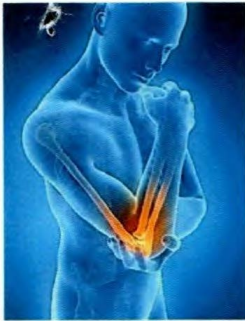


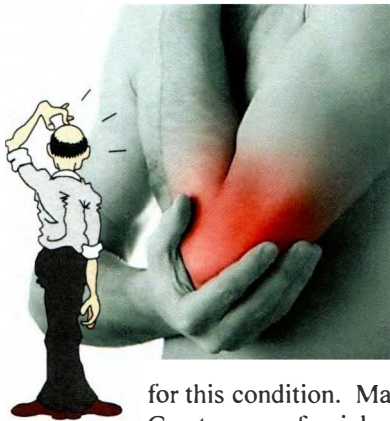
This article was dictated and written by my esteemed colleague, Dr. Michael Brown M.D. DC. Dr. Brown was a wonderful teacher and superb doctor who passed away too young. The information dictated by Dr. Brown still remains pertinent today and I corrected spelling and grammar to make it more easily readable and I find it useful to provide to my patients. I hope you like it.

Charles F Mahl M.D.



LATERAL EPICONDYLITIS: AN INTERVENTIONAL ORTHOPEDIC & REGENERATIVE MEDICINE APPROACH

INTRODUCTION:



All one has to do is begin searching the literature on the topic of lateral epicondylitis (tennis elbow) to realize that the world is scratching their head trying to figure out the most efficacious way to manage this menacing condition. We have braces, special devices, special exercise apparatus designed to treat this. Everyone has an opinion including surgeons, physiatrist, sports medicine specialist, PTs, OTs, osteopaths and chiropractors. Everyone you talk to has a different approach. We will see later on in this article as we review the topic that traditional steroid injections has been a dismal failure. Physical therapy modalities from heat, ultrasound, muscle stim, laser, shockwave therapy, and countless other physical therapy modalities have been used for this condition. Massage, friction massage, ice massage, active release technique, Graston, myofascial release, trigger point therapy, all have been used with modest improvement. We have used multiple medications including pain medication, nonsteroidal anti-inflammatory medication, creams, ointments, nitroglycerin patches, lidocaine patches, anti-inflammatory patches, herbal patches and other remedies to state just a few. We will also review the advances of regenerative medicine which has also been described over the last 10-15 years. Why is this condition causing so much confusion and why in our era of modern medicine and technology are we having such debate over such a simple condition?

Because, since the dawn of time this condition has plagued countless individuals and this condition is in fact difficult to treat. The modern day interventional orthopedic and orthopedic medicine practitioner armed with a host of regenerative medicine technology has never been better prepared to handle this condition. This condition requires an intimate understanding of tendon pathology and pathophysiology of this condition and how to apply current modern day orthopedic science and rehabilitation principles to this condition. Although this article will not be an exhaustive review of this topic we

TENNIS ELBOW LATIN FOR "MAJOR PAINUS MAXIMUS"




will review our approach and provide a basis for why we manage this condition as we do.

WHAT EXACTLY IS LATERAL EPICONDYLITIS?

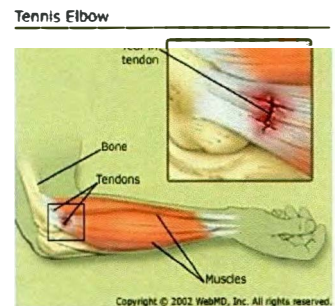
This condition is sometimes difficult to describe because it a number of clinical entities. If you look up the definition of “tennis elbow” or lateral epicondylitis a common definition used is:

A condition caused by overuse of the arm, forearm and hand muscles that results in elbow pain.

The problem is this definition really does not explain the complex of this condition. Epicondylitis or tennis elbow is actually a “tendinopathy” of varying degrees of severity which may include early insertional tears and degenerative changes within the tendon attachment to bone or may represent larger tears and other degenerative changes within the tendon commonly associated with overuse of forearm extensor muscles. Typically a muscle colored in green in the picture to the left called the extensor carpi



radialis brevis (ECRB) is one of the more common tendons affected and therefore is often associated with classic epicondylitis. The condition may also be seen in conjunction with radial collateral ligament instability and pathology that may also need to be addressed if treatment is going to be successful.

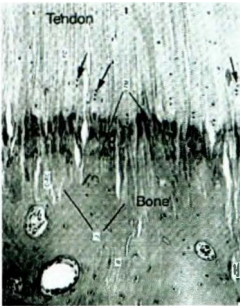


The thing that makes this more complex is that first there are several tendons in addition to the ECRB tendon that can be involved. An individual may have one or more tendons involved. And, as we will discuss, an individual can present with varying degrees of degeneration with or without traumatic or degenerative tears within the tendon or tendon attachment to bone. Therefore, some individuals have a very mild case of tendinosis and responds quite well to conservative efforts of various healthcare and allied healthcare practitioners. That fact that many respond to simple therapies perpetuates providers to apply PT and other modalities or specific soft tissue techniques as a means of treatment. If an individual does not respond in a reasonable time one needs to see a specialist capable of sorting out the degree and severity of the condition and determine the best course of action. Some individuals have more extensive degenerative changes that in fact will not be as responsive to conservative measures and therefore fail to respond to the various protocols described by many disciplines and many practitioners. It is for this very reason that I always institute a careful ultrasonography examination of the tendon and determine the severity and degree of tendinopathy before I recommend a specific treatment approach. This provides a means to predict possible treatment failure from physical therapy before we even instituted care and make decisions about different interventional strategies.

It is for this very reason that before instituting specific treatment for lateral epicondylitis/tendinosis we do a careful ultrasonography examination of the tendon to make a determination of how extensive the degenerative changes or to determine whether a tear in the tendon is present that would be a barrier to

recovery with routine physical therapy. It is by these means that we can predict the outcome of conservative treatment or intervene with regenerative injection therapies sooner to expedite recovery.

THE PATHOPHYSIOLOGY OF TENDINOSIS & TENDINOPATHY:




If one really wants to understand the chronicity of tendinopathy as well as the reasons why we currently use regenerative orthopedic medicine approaches we have to begin the discussion with some pathophysiology for those who are interested in the science behind this. In general the term “tendinopathy” suggests that the patient presents with long-standing localized activity-related pain which has had a poor response to conservative treatment.

The picture to the left is a microscopic view of the tendon attachment to bone. Note the fibers or fibular arrangements of this unique connective tissue transitions on at the bone attachment.

As humans our upper extremities are constantly busy. Many of us participate in repetitive movements and apply mechanical forces requiring grasping, torque, compression, etc. Some of us participate in recreational activities such as tennis and other sports that require repetitive tensile loads on the tendon attachment to bone. And, many of us such as those tennis players that have technique and biomechanical faults such as delayed back hand hits place repetitive stress on the tendons that begin to alter the tendon anatomy and physiology. What ever the source, cumulative stress begins to create pathologic changes within the tendon structure. As previously stated the specific tendon of the extensor carpi radialis brevis was identified back in 1979 as the predominant tendon involved in lateral epicondylitis.¹ Nirschl who identified these tendons in 79 and later described in 1992 in over 600 cases his surgical findings for tennis elbow cases where he described disrupted collagen fibers, increased cellularity and neovascularization (new blood vessel formation) in the tendons at the time of surgery.² One of the interesting findings is the lack of acute inflammatory cells.² An occasional spattering of chronic inflammatory cells were described secondary to the repair of partial tears within the tendon.² Nirschl described a term “angiofibrotic hyperplasia” a term that most specialty physicians and sports medicine physicians have used ever since.² Since this eloquent documentation by Nirschl we began to understand the tendon attachment to bone response to cumulative stress causing a degeneration of the connective tissue attachment to bone and leads to a “cheap grade” of connective tissue replacing the healthy fibrous tendon tissue which is hypervascular. This vascularized scar so to speak is subject to recurrent tears when tensile loads are applied to the tendon and a chronic cycle of injury and incomplete repair occurs.

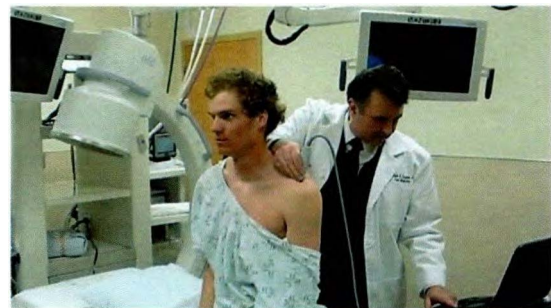
We have learned over the years that with cumulative stress the pathologic changes within the tendon include a lysis of collagen fibers, focal hypervascularity as previously described and another phenomenon which involves cellular metaplasia. This means that one type of cell changes to another type. This process is most fascinating. Stem cells exist all over our bodies and when the tendon cells begin to experience chronic stress and there is reduced blood flow to the tendon attachment there is reduced oxygen to important tenocytes that are essential for healing. The altered blood flow causes the cells to be replaced with cartilage cells. In the presence of reduced oxygen supply the replacement of cartilage cells reduces the demand for oxygen and they survive better in the



harsh environment. Typically cartilage cells require much less supply of oxygen. Unfortunately this completely changes the function of the tendon. Remember the tendon normally has a job of providing tensile strength against loads. Cartilage cells have a completely different job. Cartilage cells lay down a substance called glucosaminoglycan. This mucoid substance deposits within the tendon causing the characteristic thickening of the tendon that we see on ultrasound and MRI in individuals with tendinopathy. In addition cartilage cells can also deposit calcium hydroxyapatite which is why people with tendinopathy can also develop calcium deposits within the tendon. These degenerative changes within the tendon can then lead to load failure and small microtears. The failed healing leads to further focal hypervascularity of the connective tissue which deposits a poor grade of connective tissue with poor tensile strength. In addition chemical messengers called cytokines begin to become expressed in the local area which function to further degrade the tissue as well as stimulate pain.

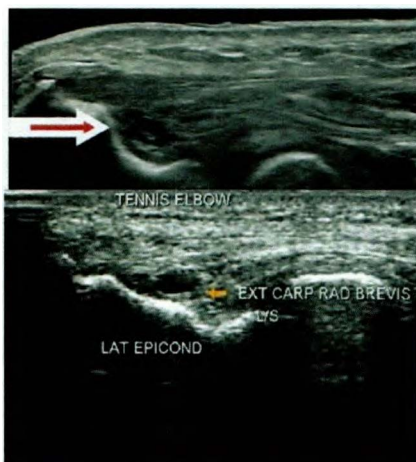
The mucoid degeneration that occurs at the tendon attachment explains what we see on ultrasound examination as well as MRI.^{3,4} It is very likely these pathologic changes create a gradual mechanical weakness and higher susceptibility to the small tendon insertion tears that we see early on in the course of disease which can ultimately lead to symptomatic tendinopathy.^{5,6}

The pathological changes in the tendon attachments can be seen in both the bone attachment sites as well as in the tendon structure itself.⁷ We utilize ultrasound imaging of the tendons, soft tissues and joints as part of our initial evaluation of all tendinopathy involving the hip, shoulder and other joints. The advancement of ultrasound technology has revolutionized the ability for subspecialty trained physicians not only to identify very specific findings in soft tissues and tendons but also to target those soft tissue structures and tendons for injection and specialized interventional procedures.



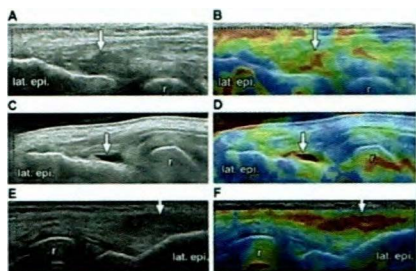
Dr. Brown examining the shoulder with ultrasound.

Tendinopathy exhibits a host of characteristic findings that can easily be seen under ultrasound or MRI. An example would be focal areas of tendon thickening or swelling as well as localized hypoechoic (dark areas) on the ultrasound image at the attachment of the tendon or within the tendon.⁸ Tendinopathy can show up as a signal abnormality on MRI and an echo abnormality on ultrasound because of the accumulation of water retaining proteoglycans that are part of the tendinopathy pathophysiology.^{7,9} A few examples of ultrasound abnormalities demonstrating tears in the extensor tendon attachment at the lateral elbow are seen below on the left. The provides an example of why ultrasound can be so valuable in the initial evaluation of lateral epicondylitis.



Tear at the extensor tendon attachment of the lateral elbow resulting in chronic lateral epicondylitis

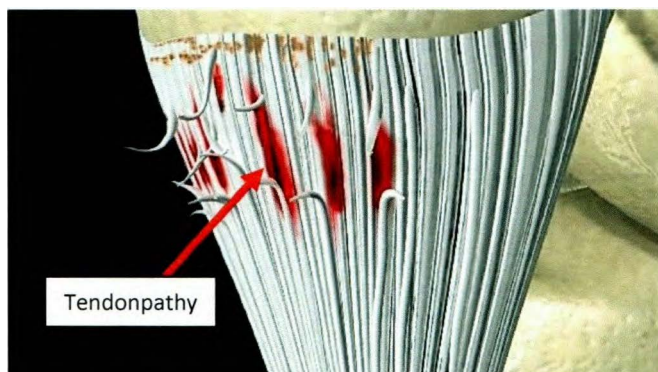
Another tear at the extensor carpi radialis brevis tendon causing chronic tennis elbow.



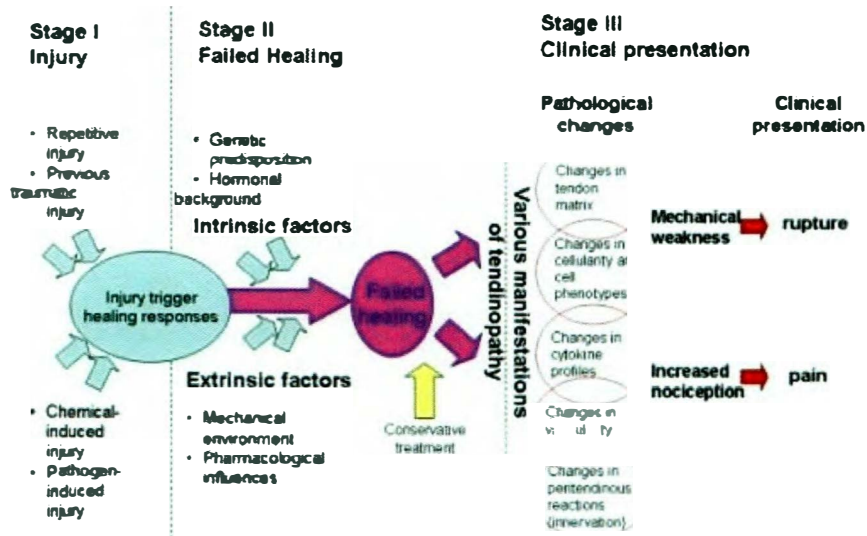
Tear of the extensor tendon attachment noted on ultrasound combined with tissue elastography a new ultrasound technique utilized on occasion.

The ultrasound findings vary with the severity from disorganized collagen fibers and focal areas of insertional tendinopathy to partial tears noted in the pictures above. We examine the tendon attachment to bone carefully as part of our physical examination process in all patients with lateral epicondylitis. Imaging findings correlate to what we now understand as tendinopathy. A recent study of 20 cases of chronic lateral epicondylitis ranging from 6 months to 48 months confirmed the abnormal tissue within the tendon which consisted of neovascularization, disrupted collagen fibers and mucoid degeneration as we have described.¹⁰ This correlated to diagnostic imaging findings.¹⁰

When we investigate tendons that demonstrate tendinopathy there are host of findings that are seen under the microscope such as changes within the collagen matrix, hypercellularity within the region of tendinopathy and hypervascularity or increased blood vessels. What we do not see is the presence of a lot of inflammatory cells.^{4,11} Focal areas of cellular death (apoptosis) can be seen which may also explain some of the imaging findings.¹² Because of various expression of cytokines which are chemicals that can alter various inflammatory responses cause the release of degradative enzymes which also further causes a deregulation of cellular activities within the tendon.¹³⁻¹⁵ Again as previously described changes in the cellular environment of the tendon which includes the appearance of cartilage like cells within the tendon also leads to calcification.^{16,17} All of these pathological changes which we have discussed in total make the tendon susceptible to mechanical stress and strain that cause the production of pro-inflammatory mediators.¹⁸⁻²¹



The process of tendon healing occurs in basically 3 phases: The initial phase involves an inflammatory response with the



influx of cellular elements. During the degenerative phase, tendon cells which likely originating in the tissue around the tendon and just within the tendon migrate to the repair site and proliferate.^{22,23} The last stage is the clinical presentation as the tendon becomes symptomatic. Chronic pain can occur thereafter which can be resistant to treatment. The physiology of tendon healing is extraordinarily complex. It involves numerous substances that stimulate a cascade of cellular activities that promote healing. Insidiously during the phase of degeneration one can see micro-ruptures in the tendon attachment to bone. Because of the various degenerative changes there is a failed healing response that ultimately leads to the persistent pain as previously described.

In summary the pathology we see changes in the tendon secondary to low oxygen supply (hypoxic degeneration). Cartilage like cells begin to deposit in the tendon laying down substances that make it susceptible to tear and degeneration. Fibrous tissue degeneration, fatty infiltration, and calcific deposits can be seen.

I have reviewed briefly some of the pathophysiology involved in tendinopathy in this article so you can begin to understand why we take the approach and specific technologies that we utilize in the treatment of this condition. We will be referencing some of the pathophysiology when we begin to describe the treatment methods. Since no inflammatory cells are typically seen within the tissue we now understand why cortisone and cortisone injections failed miserably in resolving chronic lateral epicondylitis and why regenerative orthopedic medicine approaches have revolutionized the treatment of chronic lateral epicondylitis which we will described in this document.

CAN I USE NONSTEROIDAL ANTI-INFLAMMATORY MEDICATIONS?

Many individuals with chronic tendinitis/tendinosis utilize NSAID S (nonsteroidal anti-inflammatory drugs) which are either prescribed by a physician or taken as an over-the-counter medication. Many individuals ask me whether or not they should or could use anti-inflammatory medications. The answer to that question is somewhat complicated. Let us take into consideration some of the research findings published in the literature. Interestingly, the use of NSAIDs is a double edge sword. In other words there are some beneficial effects and there are unfortunately deleterious effects. As previously stated tendon cells migrate to the area of injury and proliferate and synthesize substances important for healing. Some NSAIDs have an inhibitory effect on this process.²⁴ It is felt that prostaglandin E2 (PGE₂) which anti-inflammatory medications inhibit may be important for early tendon healing such as control of vascular flow. Reducing PGE₂ has some beneficial effects by reducing enzymes like metalloproteinases but the normal matrix remodeling would also be affected thereby contributing to a failed tendon healing.²⁵ Other concerns have been raised by researchers evaluating the effect on NSAIDs that could impede early healing process of an injured tendon—reduce tendon strength.²⁶⁻³⁰ NSAIDs have been reported to inhibit collagen synthesis in various cell types and therefore are postulated to exert a negative impact on tissue healing.^{31,32} Ibuprofen For example reduces the cellularity of the tendons and also inhibits tendon cell migration to the sites where they need to migrate to in order to stimulate proliferation and healing.^{33,34} So, the NSAIDs that we commonly use for overuse injuries, sports injuries, and the aches and pains such as trochanteric hip pain could potentially contribute to tendinopathy.²⁵

BIOMECHANICS OF TENNIS & TENNIS RELATED INJURIES:

The majority of individuals that I treat personally for lateral epicondylitis are not tennis players however since I do have a practice in Monterey California where there is a high concentration of serious tennis players I do in fact encounter a great deal of tennis players on a regular basis.



Problems that we commonly encounter are difficulties with elbow pain, shoulder pain and knee pain.



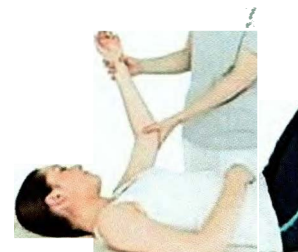The kinetic chain of tennis starts with the feet and knees and travels through the legs, trunk/back and shoulders to the elbow joint and finally through the wrist and hand. Biomechanically, the elbow functions primarily as a link in the kinetic chain, allowing transfer of kinetic energy from the body to the racquet.³⁵ High-speed video analysis reveals rather extreme forces at the elbow must repetitively absorb during tennis strokes in both flexion and extension directions.³⁶ Lateral epicondylitis is much more common in a recreational tennis player because technique errors are often at fault. In novice players for example, they strike the ball with the backhand position in a position with the wrist slightly flexed.³⁷ We see this more secondary to a slightly delayed hit of

the tennis racket where there is a combination of slower reaction time and poor technique and positioning of the hand before the strike. Biomechanical studies comparing advanced tennis players compared to novice tennis players reveal that during impact in the back hand stroke there is more eccentric muscle contraction during impact of the ball with a racquet. The term “eccentric” muscle contraction means that the muscle is lengthening as it is trying to move or support a load. In this situation at impact your wrist is slightly flexing to resist the velocity of impact of the ball onto the tennis racket. This lengthening contraction causes repetitive microtrauma which leads to the tendinosis described previously. Preventative measures are often taught to less experienced players where they are instructed to modify the back hand stroke by retraining the player to hit the ball in front of the body with the elbow and wrist extended; thus, the upper body and core muscles provide a greater contribution to the swing. This positioning also stabilizes the wrist and prevents the wrist moving into flexion and thus the eccentric excessive load applied to the extensor muscles. In addition, I often request my patients who are returning back to the sport after treatment to utilize a 2 hand back hand stroke to reduce stress on the elbow as a means of re-injury prevention.

It is a common held believe that tennis racket grip size plays a crucial role in elbow injury. This has been a subject of debate. Studies evaluating electrical activity of muscles (electromyography) of the various muscles around the elbow with varying racket grip sizes suggested that the grip size does not significantly affect forearm muscle firing patterns.^{35,38} Recently a new biomechanical study published in 2014 demonstrated that racket grip size does in fact make a significant difference.³⁹ I believe in my personal clinical experience that racquet grip size does make a difference not only for reducing stress of the forearm extensors but to reduce the effects of other wrist, hand, and elbow injuries.

TREATMENT METHODS FOR LATERAL EPICONDYLITIS:

Although one can find asymptomatic abnormalities within a tendon attachment which in some circles suggest that you cannot rely on ultrasound findings alone to determine the prognosis of treatment we utilize ultrasound extensively as part of our examination.⁴⁰ Our approach involves a comprehensive evaluation where the history, previous treatment attempts, imaging findings, chronicity, etc. is all taken into perspective in making decisions about treatment. We also feel that treatment needs to be “polymodal”. In other words there is no one single treatment that works in everyone and therefore having an understanding of biomechanics, technique correction, manual medicine, physical medicine, orthopedic and regenerative medicine techniques are critical for clinical success. For purpose of education and inpatient information we are providing some examples of treatment commonly utilized.



PHARMACOLOGY TREATMENT FOR EPICONDYLITIS:

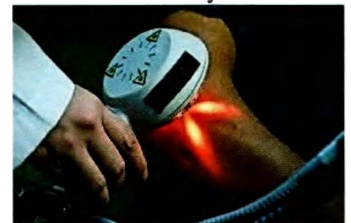Typically in an orthopedic medicine practice we do not focus on pharmacology management of epicondylitis. If we do use pharmacology it is typically to support postprocedural pain for a few days or to get an individual through a time during recovery. Since there are a lot of individuals who read this website for information and do not see me personally as a physician I will share some additional information some “tricks” for treatment of epicondylitis.

NITROGLYCERIN PATCHES: Yes, believe it or not you can cut a small portion of a Nitropatch especially the long-acting type and place it over the epicondyle and it does have a beneficial effect in some individuals.⁴¹ It is hypothesized that it has an effect on collagen and connective tissue synthesis.⁴² However if you just think about the pathophysiology there is a peripheral vascular component and tissue ischemia which may affect as well. Potential side effects could be headache, weakness, dizziness and skin irritation which has been reported in 12% of patients using this. This needs to be combined with specific stretches and eccentric exercises that we will discuss. By itself it did not demonstrate significant improvement in a recent study when compared to stretching only.⁴³

LOW-LEVEL LASER FOR EPICONDYLITIS:

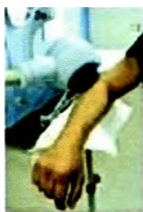There are countless therapeutic laser machines are sold to doctors and therapist these days. Unfortunately I hear a lot of practitioners making claims that are inaccurate in describing the mechanisms by which laser works with soft tissue conditions like lateral epicondylitis. That is not to say that

lasers do not have benefit. I have been a proponent of laser therapy for many years. There is research data to support this. For example Bjordal and his colleagues did a systematic review of this topic which was published in 2008 where they reviewed all of the literature and concluded there is evidence to support the use of low level laser for epicondylitis. Like everything this is not magic and should be combined with other methods of treatment. I have met countless physicists and engineers that manufacture laser machines and typically failure is blamed on the fact they used the “wrong laser”. 😊



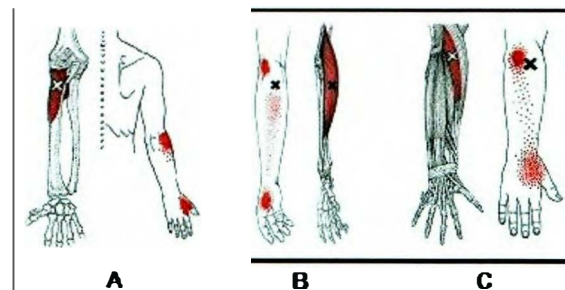
EXTRACORPORAL SHOCKWAVE THERAPY:

Patients may be offered shockwave therapy by healthcare practitioners and physical therapists. I have a number of colleagues that I am personally acquainted with, use this method and report empirically some improvement however this method is something we have not adopted in our practice and continues to remain debated. Extensive systematic reviews on the efficacy of this method of treatment have been published and since there is still been conflicting data as to whether or not this treatment is all that effective.⁴⁴⁻⁴⁶ We have not personally adopted the utilization of this technology in our practice to date.



MYOFASCIAL PAIN & TRIGGER POINTS IN LATERAL EPICONDYLITIS:

However focal areas of muscle contraction that remains a taut band within the muscle can cause localized and referred pain. Observational studies have demonstrated evidence for myofascial pain and prevalence for myofascial trigger points in lateral epicondylitis.⁴⁷ Although not yet



supported by research I believe that part of the process of tendinopathy does in fact alter muscle tone and create adaptive shortening of the muscle leading to trigger point formation in pain. C. Chan Gunn, MD a mentor of mine has long since taught that the process may occur in reverse where adaptive shortening of muscles can lead to excess tension on the tendon

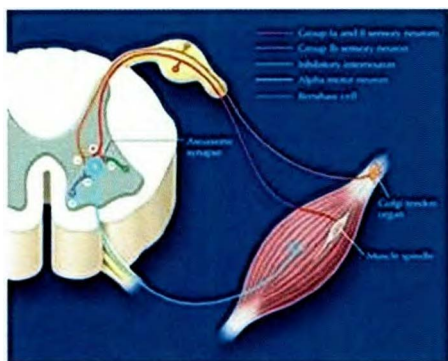
insertions causing tendinopathy and advocates for treatment of myofascial trigger points within the forearm as a means of treatment and prevention.

This may explain the beneficial effects seen clinically with various myofascial and soft tissue therapies utilized in the industry such as active release technique, various massage techniques, etc. In examination for the presence of myofascial pain and trigger points should be a part of the examination process of patient's with epicondylitis.

ACUPUNCTURE DRY NEEDLING / GUNN IMS FOR LATERAL EPICONDYLITIS:

Most individuals who are familiar with our practice are well aware that I teach nationally and internationally GUNN IMS. Although this technique is not actually acupuncture it often carries the nick

name "acupuncture dry needling" which is a term that we are going to try to eliminate in the future since IMS (Intramuscular Stimulation) which involves specific analysis and methods of treatment utilizing a needle that is used traditionally by acupuncturist. Gunn described specific methods of treating lateral elbow pain (tennis elbow) in the past and we have used this method for years.⁴⁸ There is a significant need for more research and validation of this method. However, I am somewhat biased of course and truly believe it has a place as a treatment method in a musculoskeletal clinical practice.




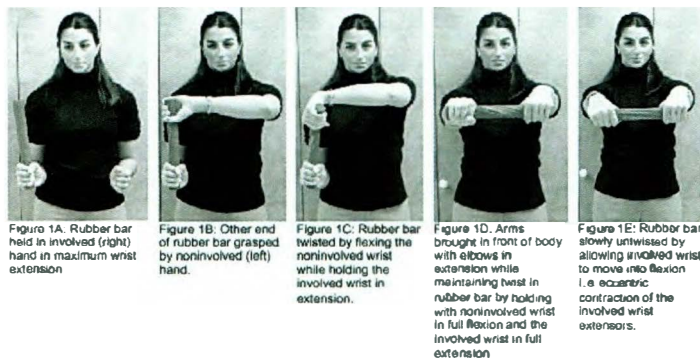
When a muscle develops trigger point and adaptive shortening, the placement of an acupuncture dry needle into the trigger point or focal area of adaptive muscle contraction can stimulate receptors within the muscle called the "muscle spindle apparatus." Stimulation of the muscle spindle sets off a reflex that resets the tone of the muscle causing immediate relaxation of the adaptive shortening of the muscle and often immediate symptomatic relief. The Gunn approach also incorporates careful examination of the cervical spine and muscles innervated by the C6 and C7 nerve roots and the muscles supplied by these nerves as also potential therapeutic targets for the acupuncture needle in cases where there is

elbow and forearm pain.

EXERCISE TREATMENT FOR LATERAL EPICONDYLITIS:

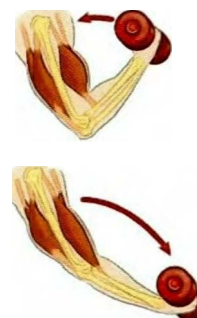
We would have to devote an entire book written on this topic to adequately cover the subject of exercise rehabilitation for lateral epicondylitis. To be somewhat brief we understand today that exercise training stimulates tendon remodeling and produces muscular adaptive responses.⁴⁹⁻⁵¹ Besides the strengthening, tissue remodeling effects and other beneficial effects of exercise there may also be a local analgesic effect of exercise.⁵² Surprisingly, few studies have investigated the sole treatment of exercise on patients with lateral epicondylitis compared to control groups or no intervention.⁵³ To be brief there has been an increase emphasis on the role of isolated eccentric strengthening exercises for lateral epicondylitis.⁵⁴⁻⁵⁶ Like many other therapies when performing a systematic review combining all research data there is still some question as to whether or not this is effective. That being said most rehabilitative professionals incorporate some type of eccentric training in the exercise programs designed for lateral epicondylitis.





THERA-BAND FlexBar®

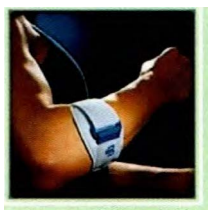Seen in these pictures is a creative tool that can be obtained from Thera-Band. This inexpensive simple tool provides a means to provide eccentric exercises for lateral epicondylitis that can be taught to a patient. Typically they utilize a maneuver noted on the right call the “Tyler Twist” technique. If you have still not figured out what “eccentric exercise” is lets clear that up right now. Imagine you are going to do a biceps curl like the



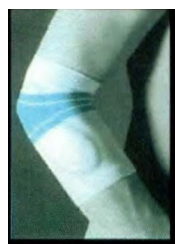If you do he will be shortening the muscle as you move the load. This is a “concentric” contraction of the muscle with a muscle shortness to move the load. If you were now to slowly lower the weight as you are extending your arm out as the bottom picture on the right your muscle is lengthening while you move the load. This is the “eccentric” contraction. The small Theraband Flex Bar provides a means that you can wind up the tension on the small tube and then allow your wrist extensors to lengthen as they slow down the unwinding of the tube. Therefore all you have to do is learn how to wind it back up using the method noted above to repeat another repetition. I think this is a clever tool and has been shown already to be clinically effective.

COUNTERFORCE BRACING FOR LATERAL EPICONDYLITIS:

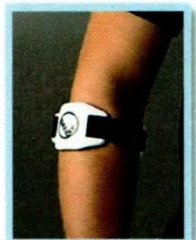Tennis elbow braces or better known as CounterForce brace is has been around for years. More and more companies are making clever devices that provide to consumers multiple choices in purchasing these types of braces. The biggest problem with the brace is that some braces create a lasting constriction around the entire forearm that can have the effect of cutting off circulation and creating pressure. Some of the more modern devices have eliminated that problem by a nonelastic band attached to a CounterForce pressure device as demonstrated in some of the samples below. CounterForce bracing theoretically inhibits full muscular expansion and therefore offload some of the pressure to the tendon attachment. Studies using an indwelling electromyography needle has demonstrated reduced extensor muscle activity at maximum isometric contraction at the tendon site when using a CounterForce brace.⁵⁷



EpiPoint Brace:
A flexible semi-rigid bar incorporated within EpiPoint helps the product retain its shape. It is washable and lined with terrycloth to for comfort and to absorb perspiration.



EpiTrain Knitted elbow support
incorporating two anatomically contoured silicone inserts surrounding the medial and lateral epicondyles and lying over the flexor and extensor muscles.



The BandIt counterforce brace: This brace provides CounterForce pressure without elastic band wrapping around the arm that some braces do and does not cut off circulation.

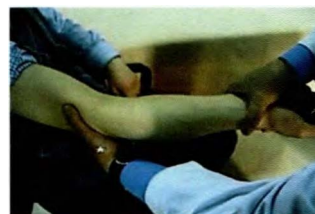

EpiSport® Tennis Elbow Brace
is another counterforce brace example made by the same company that makes EpiPoint brace.

MANUAL THERAPY FOR LATERAL EPICONDYLITIS:

Being a physician boarded in rehabilitative medicine but also a doctor of chiropractic with a background in both chiropractic and osteopathic manual therapy I do recognize the benefit of manual therapies and various musculoskeletal conditions including lateral epicondylitis. Periodically I do refer patients with lateral epicondylitis for manual therapy techniques. There are countless manual therapy techniques for this condition but more recently physical therapists have been adopting a technique called Mobilization-With-Movement (MWM) initially introduced by Mulligan in 1995 a well-known physical therapist who teaches a whole series of manipulation therapy with mobilization bands. The efficacy of this method of treatment was evaluated in 2001 demonstrating improvement and restoration of grip strength and symptoms.⁵⁸ Osteopathic muscle energy techniques have also been evaluated compared to corticosteroid injections. This study showed that while both the muscle energy manual therapy and corticosteroid demonstrated early improvement the scores were better long-term with manual therapy.⁵⁹ A simple technique they used in this study is described below that you may find useful.

The arm is stabilized as shown in the picture to the right. You try to turn your palm up until you experience some resistance or discomfort. Stop at that moment and then have someone provide resistance to turning your palm down. Push against this resistance for a period of about 5 seconds. Immediately afterwards gently turning your palm back up and you'll notice that you can go a little farther before you meet resistance or feel discomfort. This can be repeated 3-5 times.



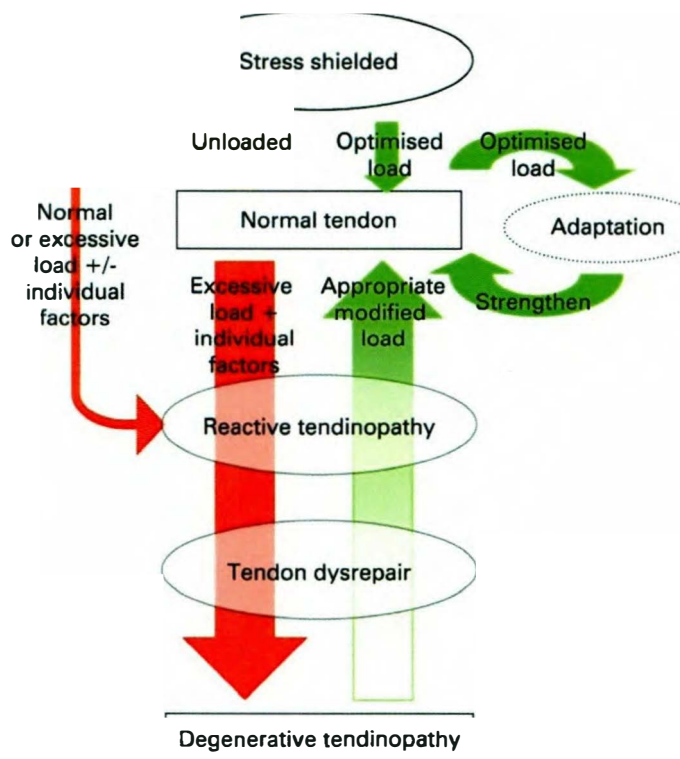
SO, WHAT EXACTLY IS CAUSING MY ELBOW PAIN?

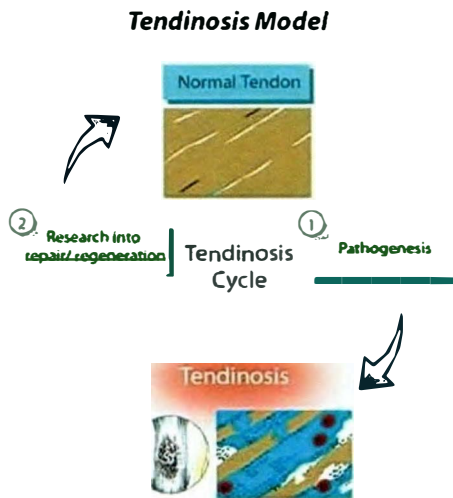


Note that we have covered basic pathophysiology and a host of various conservative treatments utilized in the treatment of lateral epicondylitis we are going to summarize the problem and why we take a regenerative medicine approach to this problem within our

practice.

Remember, that we began this discussion with a review of the degenerative changes that occur within the tendon which we called "TENDINOPATHY". Because of the degenerative changes that occur within the tendon over time there is a poor healing potential which leads to pain that often becomes resistant to various conservative measures even those described previously. We also discussed the changes within the





tendon that lead to weakening of the tendon attachment with recurrent microtears at the tendon insertion, and when attempts to heal occur there is a hypervascular, cheap grade of connective tissue that is deposited with poor healing potential.

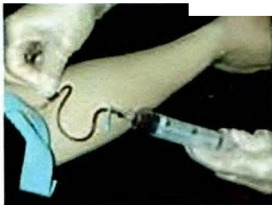
We have also stated that cartilage like cells develop and deposited substances within the tendon that thickened the tendon and further degraded due to tissue. Because of this, calcification within the tendon can also occur. This process reduces the overall tensile strength of the tendon causing the tendon to be further vulnerable to microtears and disruption.

If calcification occurs within the tendon we utilize a ultrasound guided procedure to decalcify the tendon. We have several techniques that we use for this purpose.

ORTHOPEDIC REGENERATIVE MEDICINE ON TREATMENT OF TENDINOPATHY:

Corticosteroids injected into the tendons for the treatment of tendonopathy typically only provide short-term transient relief ,may damage the connective tissue within the tendon. Many years ago we began to utilize platelets as a source of growth factors to promote healing of the degenerative changes within a tendon.

I personally began using a technique known as “prolotherapy” which is a method of treating tendonopathy and ligamentous instability of joints. The method utilizes dextrose sugar as a stimulus to promote collagen proliferation at the attachments of tendon to bone and ligament to bone. Prolotherapy can and does work with many of these tendonopathy problems. The only issue is the number of sessions required to get good treatment outcome. Frustrated with the length of time that it would take to help patients with these more complicated epicondylitis tendonopathy cases I begin searching for other alternatives. In approximately 1993 we begin to explore the use of platelets and platelet derive growth factors as a means of healing connective tissues. Today the growth factors contained in platelets are commonly used to help heal tendonopathy and insertional tears. This technique is called platelet rich plasma (PRP).




When we first began using this many physicians question the use of this but today it is one of the hottest topics in sports medicine and treatment of many soft tissue conditions. We utilize your own blood to obtain these platelets and

concentrate them for therapeutic use.

With a simple blood draw your blood can be centrifuged and processed in such a way to remove the red cells from your blood and the majority of your plasma, which is the fluid that your blood

circulates in. We concentrate the platelets and once transferred to a syringe can be a “cellular transplant” that can be injected at the insertion sites and tears within the tendon of the elbow. This can also be used for ligament instability as well. We also utilize advanced platelet preparations where we activate platelets to extract growth factors and filter platelet cell bodies from the mixture using pure growth factors rather than cells. We have used platelet derived growth factors and platelet rich plasma on thousand the patients and have accumulated a great deal of experience since we were one of the first to use this technique.



DOES PRP WORK FOR LATERAL EPICONDYLITIS?

Well, that depends on who you talk to. Physicians utilizing various regenerative medicine techniques empirically can state they have numerous cases where they have had excellent outcome. There has been almost 700 articles written on this topic to date. 50% state the treatment works and 50% state the treatment does not. After years of evaluation of these randomized clinical control trials we have finally come to realize that it depends on the method of preparation of platelet rich plasma. Therefore, someone needs to really understand what they are doing when preparing PRP. There are a multitude of method used to prepare PRP which makes a significant difference as to whether or not it will work for lateral epicondylitis or not. Physicians utilizing PRP should be keenly aware of the preparation process that provides the best efficacy for lateral epicondylitis.

We would like to say we “cure” everyone with a single platelet rich plasma injection but unfortunately such as not the case. There is tremendous variability from individual to individual and we have fortunately learned that there are many other advanced regenerative medicine techniques that can be utilized besides PRP. If we suspect that there is a larger tear in the tissues we have other methods such as combining stem cells and fat that enhance the healing effect of the platelets. It is taken almost 10-15 years of experimentation and practice to understand all of the different nuances in cellular preparation that improve the efficacy of this treatment.

There has been studies published evaluating the outcome of platelet rich plasma on lateral epicondylitis. Misra in 2006 was one of the first orthopedist to provide a small outcome study on the use of PRP for epicondylitis.⁶⁰ He treated 20 patients with epicondylitis which had failed treatment as well as injections of steroid. This was a double blind study where 15 of the patients received platelet plasma injections and 5 received a placebo injection of local anesthetic. At 6 months PRP patient’s noted 81% improvement in their pain scores and at 1-2 years patients receiving PRP reported 93% improvement. We witnessed an explosion in the use of this following the publication of the small study. Since that time multiple studies have been done.⁶¹⁻⁶³

Typically most patients have resolution of symptoms after a single PRP injection and occasionally we have to use 2 treatments. Most physicians utilizing PRP recommend 3 treatments and on rare occasions we have had to use as many as 3 treatments to resolve severe tendinopathy.

STEM CELL AND OTHER ORTHO-BIOLOGIC TREATMENT:

Typically patients do not require more advanced stem cell therapies or other ortho biologic treatment for a case of epicondylitis. On occasion the patient may present with a tear that we feel may not heal with platelet rich plasma. In those situations I will advise patient's on the case-by-case basis to consider other cellular therapy such as stem cell treatment. We utilize a autologous scaffolding enhanced by stem cells treatments that obtain from your body (autologous) to "lock in" to the tear and stimulate healing. We also have numerous other advanced stem cell and regenerative injection techniques that we can use in conjunction with platelet rich plasma and/or the growth factors obtained from platelet rich plasma.

WHAT CAN I EXPECT FROM PLATELET RICH PLASMA INJECTION TREATMENT? Again we have been using this method of treatment to treat epicondylitis for many years. We have used multiple methods of cellular preparation and laboratory techniques and we also had to experiment on countless occasions using various techniques to learn how to use this method of treatment effectively. There are several key elements that the patient needs to understand when undergoing this method of treatment.

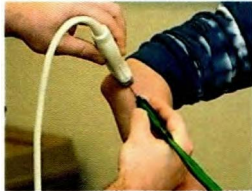First, this is not a corticosteroid injection where you will experience immediate symptomatic relief the following day after treatment. The growth factors contained within platelets stimulate a cascade of healing events and actually set off localized pain that can last for days or weeks following the injections. Occasionally an individual may have pain for a protracted period of time. Yes, you do have to put up with some increased pain for a period of time as a part of the treatment process.

To treat the postinjection flare we typically recommend hot packs and Tylenol although periodically we find it can be helpful to use a short-term course of opioid medications such as hydrocodone or tramadol². We do this for a short period of time and **do not typically recommend nonsteroidal anti-inflammatory medications** since it may interfere with potential healing as we have described previously. One has to realize the complexity of the pathology and also realize that your body is going to need time to heal and may require under some circumstances additional treatment.

It is surprising despite providing all of the information we do with regards to the pathophysiology, the extent of tendon degenerative change, and all of the precipitating factors how many individuals show up expecting to have some "magical" injection treatment on a one-time basis that will resolve all their problems. The connective tissue repair requires soft tissue engineering strategies using tissue growth factors and sometimes more sophisticated methods of treatment including biomechanical correction, lifestyle changes, etc. In addition, there are times when we have to use a poly-modal approach meaning multiple different types of treatment at the same time which could include acupuncture dry needling, soft tissue mobilization techniques, manual in physical therapy and counterforce bracing after injection therapy.

TENEX FAST PROCEDURE: NEW ULTRASOUND-GUIDED MICROSURGICAL TECHNOLOGY FOR LATERAL EPICONDYLITIS:

The **FAST procedure** (FOCUSED ASPIRATION OF SCAR TISSUE) presents a breakthrough in orthopedic technology. A number of years ago ophthalmologists developed a small micro-probe that could be inserted into the lens of the eye and a high-frequency ultrasound wave could be transmitted through the probe which they can vaporize coagulated proteins that cause a cataract. Years later this technology was advanced for the use of clearing out the “cheap grade of tissue which is a combination of hypervascularity and scar. Researchers were to discover that when a similar probe is placed within the scar tissue of a tendon the same ultrasound frequency that vaporized cataracts also vaporized scar tissue within the tendon. This discovery was a huge breakthrough in orthopedic microsurgical technique.



This technique requires an experience and understanding of ultrasound technology since this procedure is done under the guidance of ultrasound. During this microsurgical procedure which is done

under local anesthetic a small probe is guided into the tendon under the guidance of ultrasound (simulated in the picture to the left) and the tip of the probe is guided into the diseased portion of the tendon.

The small probe that is inserted into the tendon has a small opening in the tip where a small jet of saline shoots out the tip where it is immediately vacuumed back in.



The circular motion of the saline flowing in and out of the probe provides a means to vacuum up the vaporized scar tissue back into the probe where it is deposited into a small container inside the machine. This is of course completely sterile, self-contained probe system and discarded into hazardous waste following the procedure. Remember, we have discussed the pathophysiology of tendinopathy. Now imagine a special tool that can be inserted into a tendon and the “bad tissue” can be vaporized and removed but the tool does not disturb healthy tendon tissue nearby. This has created a revolution in orthopedic surgical procedures.

The TENEX FAST procedure can be used for many applications and not just for the elbow but for the shoulder and the hip as well. Advanced musculoskeletal practitioners are finding more and more creative ways to utilize this special technology. There are times when it is more appropriate to consider doing this procedure when there is a focal area that we do not feel will fill back in and heal by simple PRP or other cellular therapies. Sometimes it is much more appropriate to vaporize or do a debridement with this technology and the tissue will heal very rapidly. In other words remove the scar that is interfering with healing and you get a rapid resolution of the problem. I have combined the FAST procedure + done PRP injections to enhance healing and resolution of stubborn epicondylitis cases in the past.

<http://www.tenexfastprocedure.com/medication-adhd-tenex-houston-tx.html>

<http://www.tenexhealth.com/explore-tenex-health/how-does-it-work>

<http://www.tenexhealth.com/>

RADIOFREQUENCY PERCUTANEOUS THERMAL LESIONING FOR LATERAL EPICONDYLITIS:

For the sake of completeness there are other procedures that can be done. We have been using radiofrequency thermal lesioning for many years in pain medicine. This involves utilizing a radiofrequency electrode which basically looks like a needle. The radiofrequency needle is inserted under ultrasound guidance and moved into the area of tissue pathology. The radiofrequency lesioning coagulates the diseased and hypervascular scar tissue. No incision is required. Lin and his colleagues in his paper published reported 34 patient's with persistent lateral epicondylitis were treated using radiofrequency ablation with a reported 85% success. We prefer today to use the TENEX FAST procedure over radiofrequency but we do have this technology available as an option.

IN SUMMARY:

Although lateral epicondylitis represents a focal area of tissue degeneration and tendinopathy and over the years has been known for being somewhat recalcitrant to treatment, monitored orthopedic medicine and interventional orthopedic procedures utilizing various regenerative medicine approaches has revolutionized the treatment of this disorder.

REFERENCES:

1. Nirschl R, Pettrone F. Tennis elbow: The surgical treatment of lateral epicondylitis. *J Bone Jt Surg.* 1979;61(A):832-839.
2. Nirschl R. Elbow tendinosis/Tennis elbow. *Clin Sports Med.* 1992;11:851-870.

3. Kannus P, Józsa L. Histopathological changes preceding spontaneous rupture of a tendon. A controlled study of 891 patients. *J Bone Joint Surg Am* 1991, 73(10):1507-1525.
4. Movin T, Gad A, Reinholt F, Rolf C. Tendon pathology in long-standing achillodynia. Biopsy findings in 40 patients. *Acta Orthop Scand* 1997, 68:170-175.
5. Järvinen M, Józsa L, Kannus P, Järvinen T, Kvist M, Leadbetter W. Histopathological findings in chronic tendon disorders. *Scand J Med Sci Sports* 1997, 7(2):86-95.
6. Tallon C, Maffulli N, Ewen S. Ruptured Achilles tendons are significantly more degenerated than tendinopathic tendons. *Med Sci Sports Exerc* 2001, 33(12):1983-1990.
7. Movin T, Kristoffersen-Wiberg M, Shalab iA, Gad A, Aspelin P, Rolf C. Intratendinous alterations as imaged by ultrasound and contrast medium-enhanced magnetic resonance in chronic achillodynia. *Foot Ankle Int* 1998, 19(5):311-317.
8. McLoughlin R, Raber E, Vellet A, Wiley J, Bray R. Patellar tendinitis: MR imaging features, with suggested pathogenesis and proposed classification. *Radiology* 1995, 197(3):843-848.
9. Knobloch K, Schreibmueller L, Meller R, Busch KH, Spies M, Vogt P. Superior Achilles tendon microcirculation in tendinopathy among symptomatic female versus male patients. *Am J Sports Med* 2008, 36(3):509-514.
10. Potter H, Hannafin J, Morwessel R, al. e. Lateral epicondylitis: Correlation of MR imaging, surgical, and histopathologic findings. *Radiology*. 1995;196:43-46.
11. Rolf C, Fu B, Pau A, Wang W, Chan B. Increased cell proliferation and associated expression of PDGFRbeta causing hypercellularity in patellar
12. Lian Ø, Scott A, Engebretsen L, Bah rR, Duronio V, Khan K. Excessive apoptosis in patellar tendinopathy in athletes. *Am J Sports Med* 2007, 35(4):605-611.
13. Fu S, Chan B, Wang W, Pau H, Chan K, Rolf C. Increased expression of matrix metalloproteinase 1 (MMP1) in 11 patients with patellar tendinosis. *Acta Orthop Scand* 2002, 73(6):658-662.
14. Fu S, Wang W, Pau H, Wong Y, Chan K, Rolf C. Increased expression of transforming growth factor-beta1 in patellar tendinosis. *Clin Orthop Relat Res* 2002, (400):174-183.
15. Nakama L, King K, Abrahamsson S, Rempel D. VEGF, VEGFR-1, and CTGF cell densities in tendon are increased with cyclical loading: An in vivo tendinopathy model. *J Orthop Res* 2006, 24(3):393-400.
16. Uthoff H. Calcifying tendinitis, an active cell-mediated calcification. *Virchows Arch A Pathol Anat Histol* 1975, 366(1):51-58.
17. de Mos M, Koevoet W, van Schie H, et al. In vitro model to study chondrogenic differentiation in tendinopathy. *Am J Sports Med* 2009, 37(6):1214-1222.
18. Bosch U, Zeichen J, Skutek M, Albers I, van Griensven M, Gässler N. Effect of cyclical stretch on matrix synthesis of human patellar tendon cells. *Unfallchirurg* 2002, 105(5):437-442.
19. Wang J, Jia F, Yang G, et al. Cyclic mechanical stretching of human tendon fibroblasts increases the production of prostaglandin E2 and levels of cyclooxygenase expression: a novel in vitro model study. *Connect Tissue Res* 2003, 44(3-4):128-133.
20. Li Z, Yang G, Khan M, Stone D, Woo S, Wang J. Inflammatory response of human tendon fibroblasts to cyclic mechanical stretching. *Am J Sports Med* 2004, 32(2):435-440.
21. Yang G, Im H, Wang, JH. Repetitive mechanical stretching modulates IL-1beta induced COX-2, MMP-1 expression, and PGE2 production in human patellar tendon fibroblasts. *Gene* 2005, 363:166-172.
22. Russell JE, PR. M. Collagen synthesis during primate flexor tendon repair in vitro. *J Orthop Res* 8:13-20.1990.
23. Gelberman R, Amiel D, F. H. Genetic expression for type I procollagen in the early stages of flexor tendon healing. *J Hand Surg* 17A:551- 558. 1992.
24. Riley G, Cox M, Harrall R, Clements S, Halem B. Inhibition of tendon cell proliferation and matrix glycosaminoglycan synthesis by nonsteroidal anti-inflammatory drugs in vitro. *Journal of Hand Surgery (British and European Volume, 2001)* 26B: 3: 224-228.

25. Chan K, Fu S. Anti-inflammatory management for tendon injuries-friend or foes? *Sports Medicine, Arthroscopy, Rehabilitation, Therapy & Technology Sports Medicine, Arthroscopy, Rehabilitation, Therapy & Technology* 2009; 1:23 p 1-3.
26. DS. M. Comparative study of ibuprofen and aspirin in soft-tissue injuries. *Rheumatol Rehabil* 1974;13:141-147.
27. Nishimura K, Nakamura R, diZerega G. Ibuprofeninhibition of postsurgical adhesion formation: a time and dose response biochemical evaluation in rabbits. *J Surg Res.* 1984;36:1:15-124.
28. Kulick M, Smith S, Hadler K. Oral ibuprofen: evaluation of its effect on peritendinous adhesions and the breaking strength of a tenorrhaphy. *J Hand Surg [Am]* 1985;11:110-120.
29. Ferry S, Dahners L, Afshari H, al. e. The effects of common anti-inflammatory drugs on the healing rat patellar tendon. *Am J Sports Med.* 2007;35:1326-1333.
30. Cohen D, Kawamura S, Ehteshami J, al. e. Indomethacin and celecoxib impair rotator cuff tendon-tobone healing. *Am J Sports Med* 2006;34:262-269.
31. Nishi O, Nishi K, Fujiwara T, al. e. Effects of diclofenac sodium and indomethacin on proliferation and collagen synthesis of lens epithelial cells in vitro. *J Cataract Refract Surg.* 1995;21:461-465.
32. Matsumoto H, Fujii A. Tenidap, an anti-inflammatory agent, inhibits DNA and collagen syntheses, depresses cell proliferation, and lowers intracellular pH in cultured human gingival fibroblasts. *J Pharmacol Exp Ther.* 2002;300:668-672.
33. Tsai W, Hsu C, Chang H, Lin Y, Lin M, Pang J. Ibuprofen inhibits tendon cell migration in a process that is probably mediated by the down-regulation of paxillin. *J Orthop Res.* 2006;24:551-558.
34. Tsai W, Hsu C, Chang H, Yu-Chun Lin Y, Lin M, Pang J. Ibuprofen Upregulates Expressions of Matrix Metalloproteinase-1, -8, -9, and -13 without Affecting Expressions of Types I and III Collagen in Tendon Cells. *J Orthop Res* 2010;28:287-291.
35. Eygendaal D, Rahussen F, Diercks R. Biomechanics of the elbow joint in tennis players and relation to pathology. *Br J Sports Med.* 2007;41:820-822.
36. Kibler W. Clinical biomechanics of the elbow in tennis: implications for evaluation and diagnosis. *Med Sci Sports Exerc* 1994;26:1203-1206.
37. Blackwell J, Cole K. Wrist kinematics differ in expert and novice tennis players performing the backhand stroke. Implications for tennis elbow. *J Biomech.* 1994;27:508-516.
38. Hatch Gr, Pink M, Mohr K, al. e. The effect of tennis racket grip size on forearm muscle firing patterns. *Am J Sports Med* 2006;34:177-183.
39. Rossi J, Vigouroux L, Barla C, Berton E. Potential effects of racket grip size on lateral epicondylalgia risks. *Scand J Med Sci Sports.* 2014;doi: 10.1111/sms.12204:1-9.
40. Cook J, Khan K, Kiss Z, al. e. Asymptomatic hypoechoic regions on patellar tendon ultrasound: A 4-year clinical and ultrasound followup of 46 tendons. *Scand J Med Sci Sports.* 2001;11:3-1-327.
41. Paoloni J, ., Appleyard R, Nelson J, al. e. Topical nitric oxide application in the treatment of chronic extensor tendinosis at the elbow: a randomized, doubleblinded, placebo-controlled clinical trial. *Am J Sports Med* 2003;31:915-920.
42. Murrell G. Using nitric oxide to treat tendinopathy. *Br J Sports Med.* 2007;41:227-231.
43. Paoloni J, Murrell G, ., Burch R, al. e. Randomised, Double Blind, Placebo Controlled, Multicentre Dose-Ranging Clinical Trial of a New Topical Glyceryl Trinitrate Patch for Chronic Lateral Epicondylitis. *Br J Sports Med.* 2009;43:299-302.
44. Buchbinder R, Green S, Youd J, al. e. Systematic review of the efficacy and safety of shock wave therapy for lateral elbow pain. *J Rheumatol* 2006;33:1351-1363.
45. Rompe J, Maffulli N. Repetitive shock wave therapy for lateral elbow tendinopathy (tennis elbow): a systematic and qualitative analysis. *Br Med Bull.* 2007;88:355-378.
46. Buchbinder R, Green S, Youd J, Assendelft W, Barnsley L, Smidt N. Shock wave therapy for lateral elbow pain. *Cochrane Database Syst Rev* 2005;(4):CD003524.

47. Shmushkevich Y, Kalichman L. Myofascial pain in lateral epicondylalgia: A review. *Journal of Bodywork & Movement Therapies*. 2013;17:434-439.
48. Gunn C, Milbrandt W. Tennis elbow and the cervical spine. . *Can Med Assoc J*. 1976;114:803-809.
49. Kjaer M. Role of extracellular matrix in adaptation of tendon and skeletal muscle to mechanical loading. *Physiol Rev* 2004; 84: 649-98.
50. Wang J. Mechanobiology of tendon. *J Biomech* 2006; 39: 1563-82.
51. Langberg H, Ellingsgaard H, Madsen T, al. e. Eccentric rehabilitation exercise increases peritendinous type I collagen synthesis in humans with Achilles tendinosis. *Scand J Med Sci Sports* 2007; 17: 61-6.
52. O'Leary S, Falla D, Hodges P, al. e. Specific therapeutic exercise of the neck induces immediate local hypoalgesia. *J Pain* 2007; 8: 832-839.
53. Bisset L, Paungmali A, Vicenzino B, al. e. A systematic review and meta-analysis of clinical trials on physical interventions for lateral epicondylalgia. *Br J Sports Med* 2005 ;39: 411-422; discussion 4114-22.
54. Langberg H, Ellingsgaard H, Madsen T, al. e. Eccentric rehabilitation exercise increases peritendinous type I collagen synthesis in humans with Achilles tendinosis. *Scand J Med Sci Sports* 2007; 17: 61-66.
55. Croisie rJ, Foidart-Dessalle M, Tinan tF, al. e. An isokinetic eccentric programme for the management of chronic lateral epicondylar tendinopathy. *Br J Sports Med* 2007; 41: 269-275.
56. Woodley B, Newsham-West R, Baxter G. Chronic tendinopathy: effectiveness of eccentric exercise. *Br J Sports Med* 2007; 41: 188-198; discussion 199.
57. L. S-M, M. E. Effect of standard and Aircast tennis elbow bands on integrated electromyography of forearm extensor musculature proximal to the bands. *Am J Sports Med*. 1989;17 :278-281.
58. B. Vicenzino, A. Paungmali, S. Buratowski, Wright A. Specific manipulative therapy treatment for chronic lateral epicondylalgia produces uniquely characteristic hypoalgesia .*Manual Therapy*: (2001) 6(4), 205-212.
59. S. K, Yilmaz H, Salli A, Uğurlu H. Muscle Energy Technique Versus Corticosteroid Injection for Management of Chronic Lateral Epicondylitis: Randomized Controlled Trial With 1-Year Follow-up. *Archives of Physical Medicine and Rehabilitation* 2013; 94: 2068-2074
60. Treatment of chronic elbow tendinosis with buffered platelet-rich plasma. *Am J Sports Med*. . Epub May 30 2006;34(11):1774-1778.
61. Gosens T, Peerbooms J, van Laar W, al. e. Ongoing positive effect of platelet-rich plasma versus corticosteroid injection in lateral epicondylitis: a double-blind randomized controlled trial with 2-year follow-up. . *Am J Sports Med*. . 2011;39:1200-1208.
62. Peerbooms J, Sluimer J, Bruijn D, Gosens LMBT. Positive effect of an autologous platelet concentrate in lateral epicondylitis in a doubleblind randomized controlled trial: platelet-rich plasma versus corticosteroid injection with a 1-year follow-up. . *Am J Sports Med*. 2010;18(2):255-262.
63. Thanasas C, Papadimitriou G, Charalambidis C, al. e. Platelet-rich plasma versus autologous whole blood for the treatment of chronic lateral elbow epicondylitis: a randomized controlled clinical trial. . *Am J Sports Med*. 2011 39:12:30-1234.
64. Patrella R, Cogilano A, Decaria J, Mohamed N, Lee R. Management of tennis elbow with sodium hyaluronate periarticular injections. *Sports Med Arthrosc Rehabil Ther Technol*. February 2010;2:4.